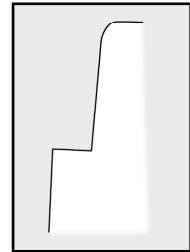


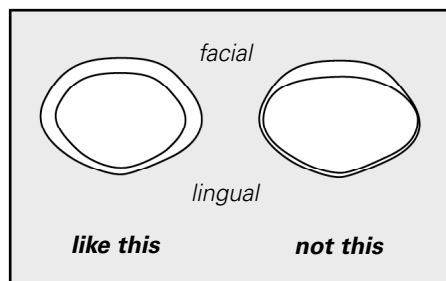
Porcelain Margins

With metal ceramic restorations, the porcelain margin is a popular technique to improve esthetics in the margin area. The technique allows margin placement without the “black line” that is so often present with many metal ceramic restorations. As the volume of these cases increase, so have the problems resulting in poor results or failures. We have a few suggestions to improve the success rate of your restorations.

The single most important factor to consider with any porcelain margin technique is to simply make the margin a flat right-angled “butt-joint,” as traditional porcelain jacket butt-joint margin (fig. a). The right-angled preparation must be accomplished with a flat end bur such as the Brassler 558 and finished with a flat end diamond such as the 846. A round end or tapered bur can not create this right-angled preparation for a proper butt-joint margin.



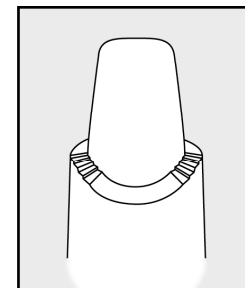
(fig. a)



(fig. b)

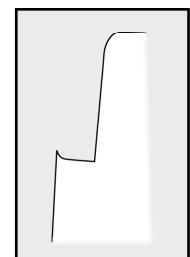
A second very important consideration and source of considerable frustration, and disappointment, with many of these restorations is the failure to carry the shoulder *through* the proximal embrasure area (fig. b). Failure to do so will result in the porcelain margin’s transition back to the metal ceramic margin in the facial/visible area. The shoulder should be carried two-third’s (facially) of the tooth to ensure good porcelain esthetics well into the proximal embrasure area.

Another common problem is the failure to smooth out “bumps” on the mesial and the distal shoulders as the bur progresses up and down the line angles. A “stairstep” effect often results which should be refined with a flat end diamond and/or hand instrument (fig. c).

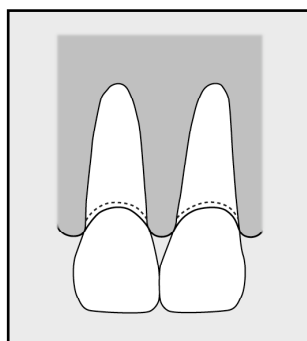


(fig. c)

A fourth point to consider is the “lip” that is created if a narrow or round end bur is used to made the prep (fig. d). This small fragile lip (edge of enamel) will easily fracture and should be smoothed off with a flat end diamond and/or hand instrument prior to impression.



(fig. d)



A final consideration is actual margin placement relative to the sulcus. It is critical on esthetic cases to place the margin .5 – 1.0mm into the sulcus (sub-gingival), to allow for proper crown contours and closed gingival embrasures. Even equa-gingival margin placement makes it almost impossible to close the gingival embrasures with proper crown contours (fig. e).

(fig. e)

Bay View Dental Laboratory

1207 Volvo Parkway, Chesapeake, VA 23320-7654

757.583.1787

www.BVDL.com or info@BVDL.com